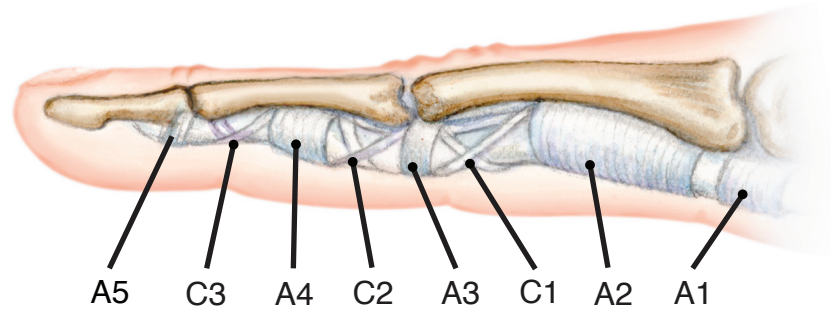


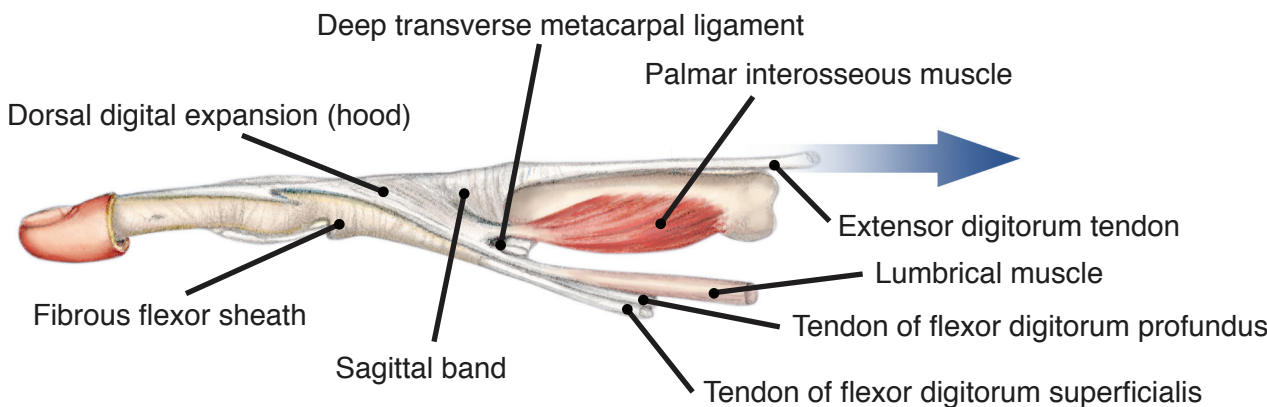
Hand and Wrist Anatomy

ANNULAR & CRUCIATE PULLEYS OF FLEXOR TENDON SHEATH

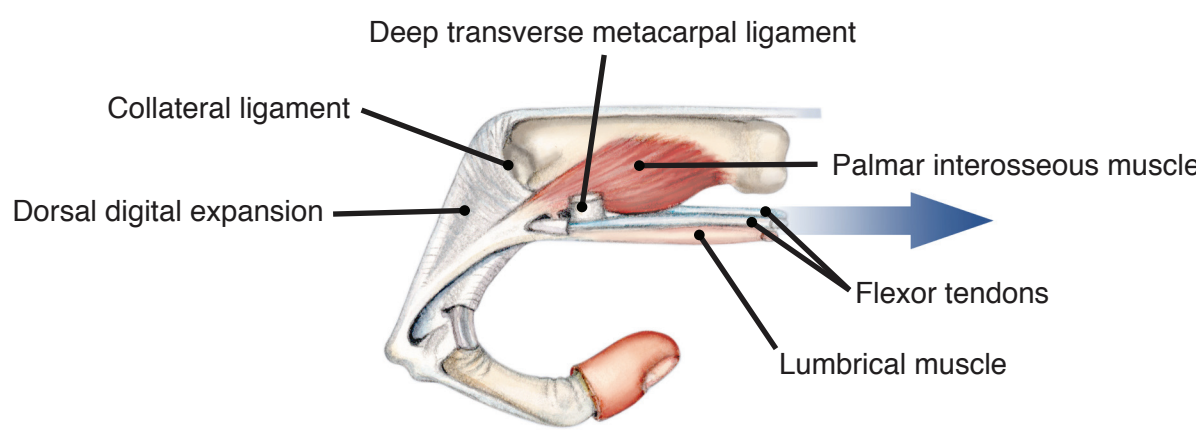


FLEXION AND EXTENSION OF FINGER

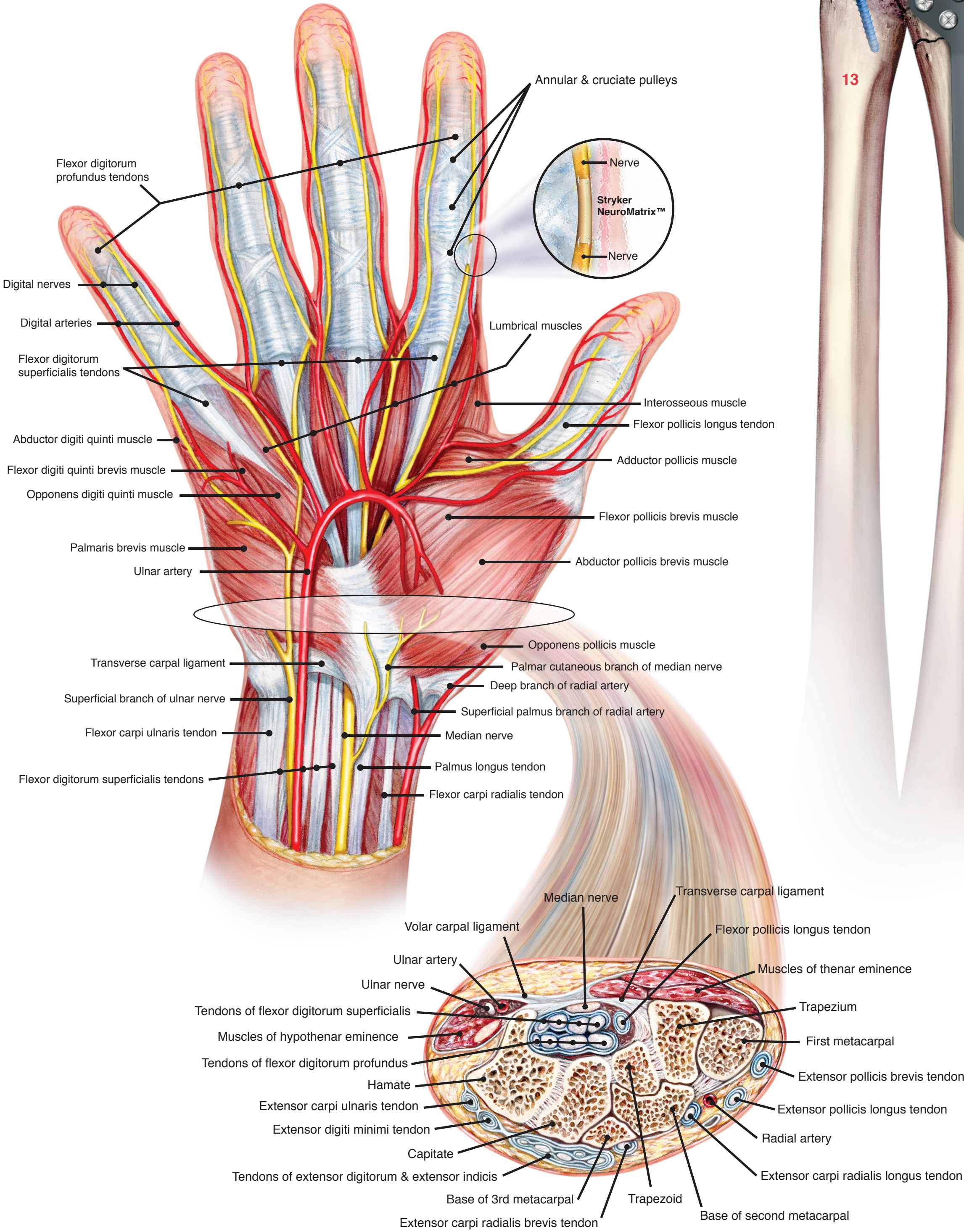
EXTENSION



FLEXION

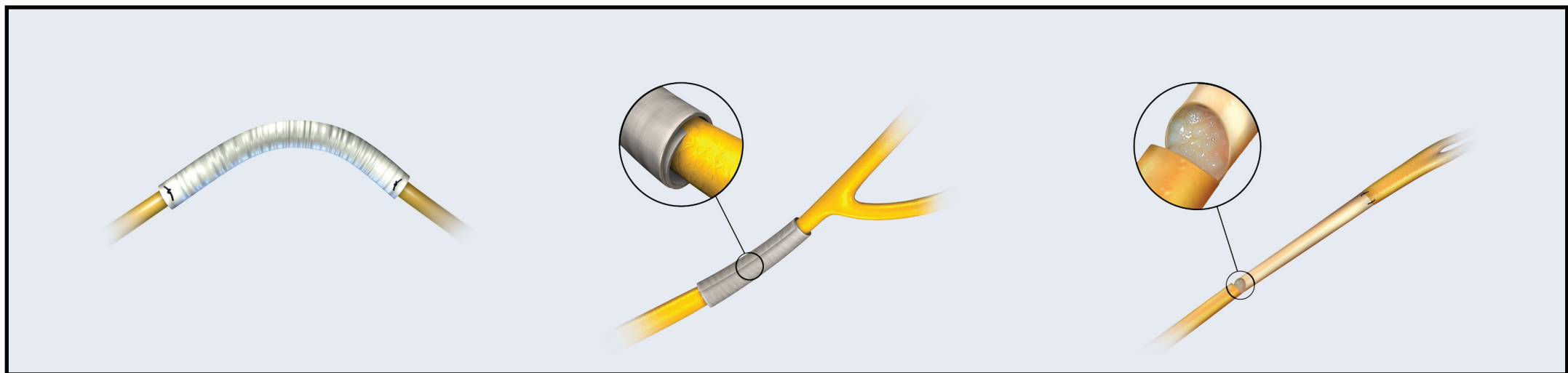


ANATOMY OF VOLAR HAND

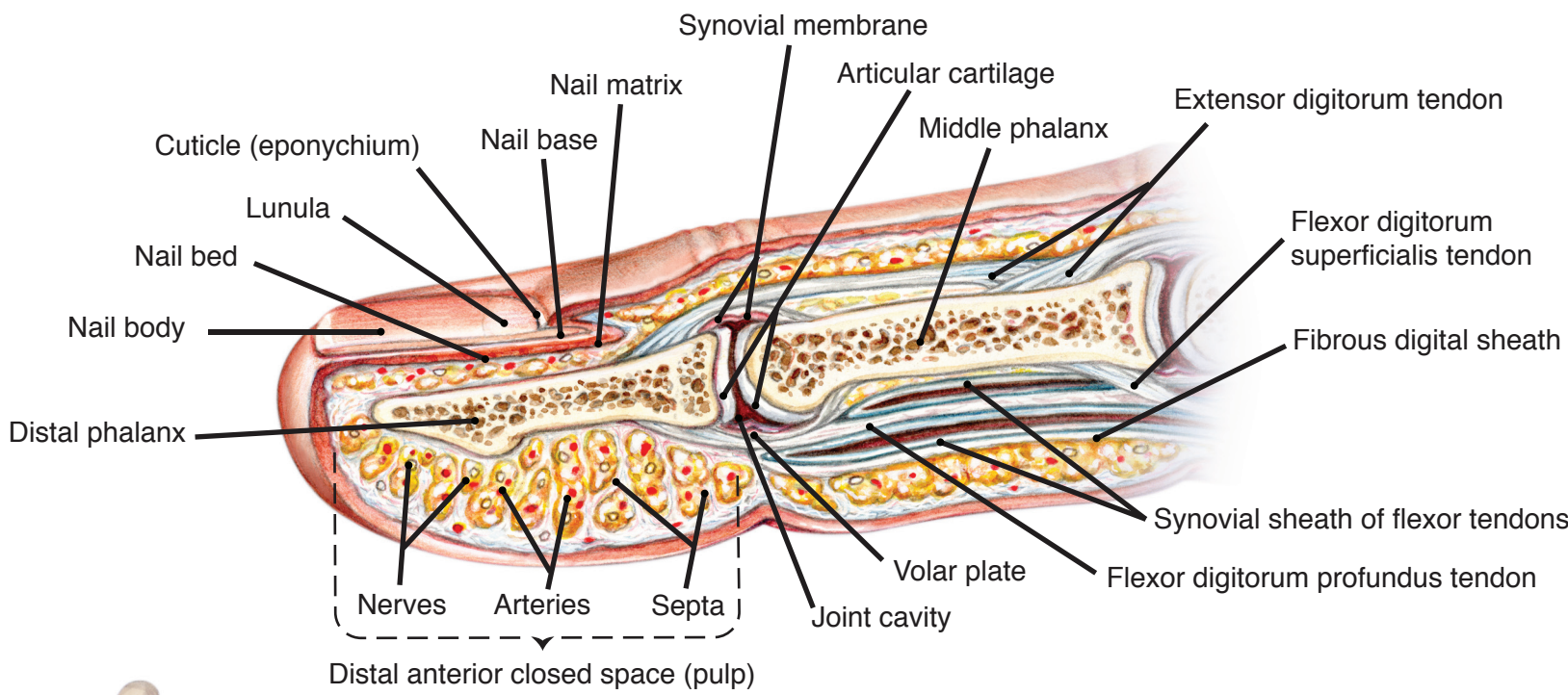


CROSECTION OF WRIST

Stryker Nerve Repair System



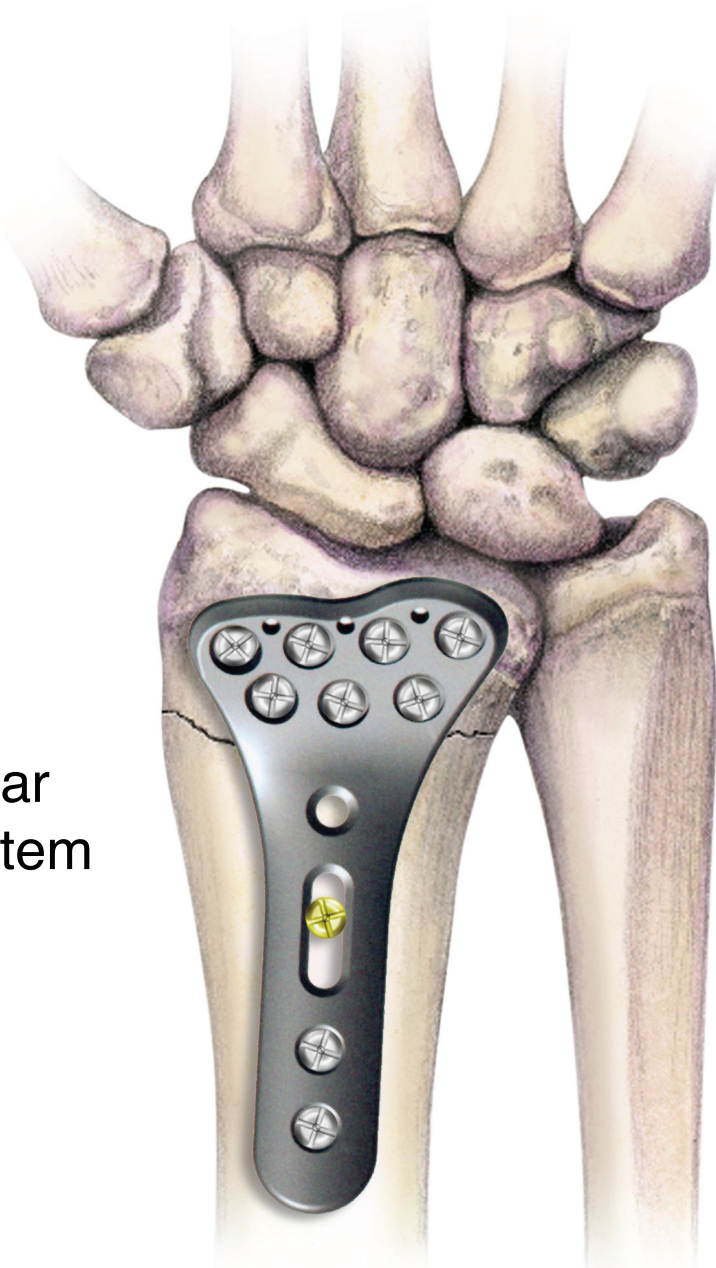
SAGITTAL SECTION THROUGH DIGITS



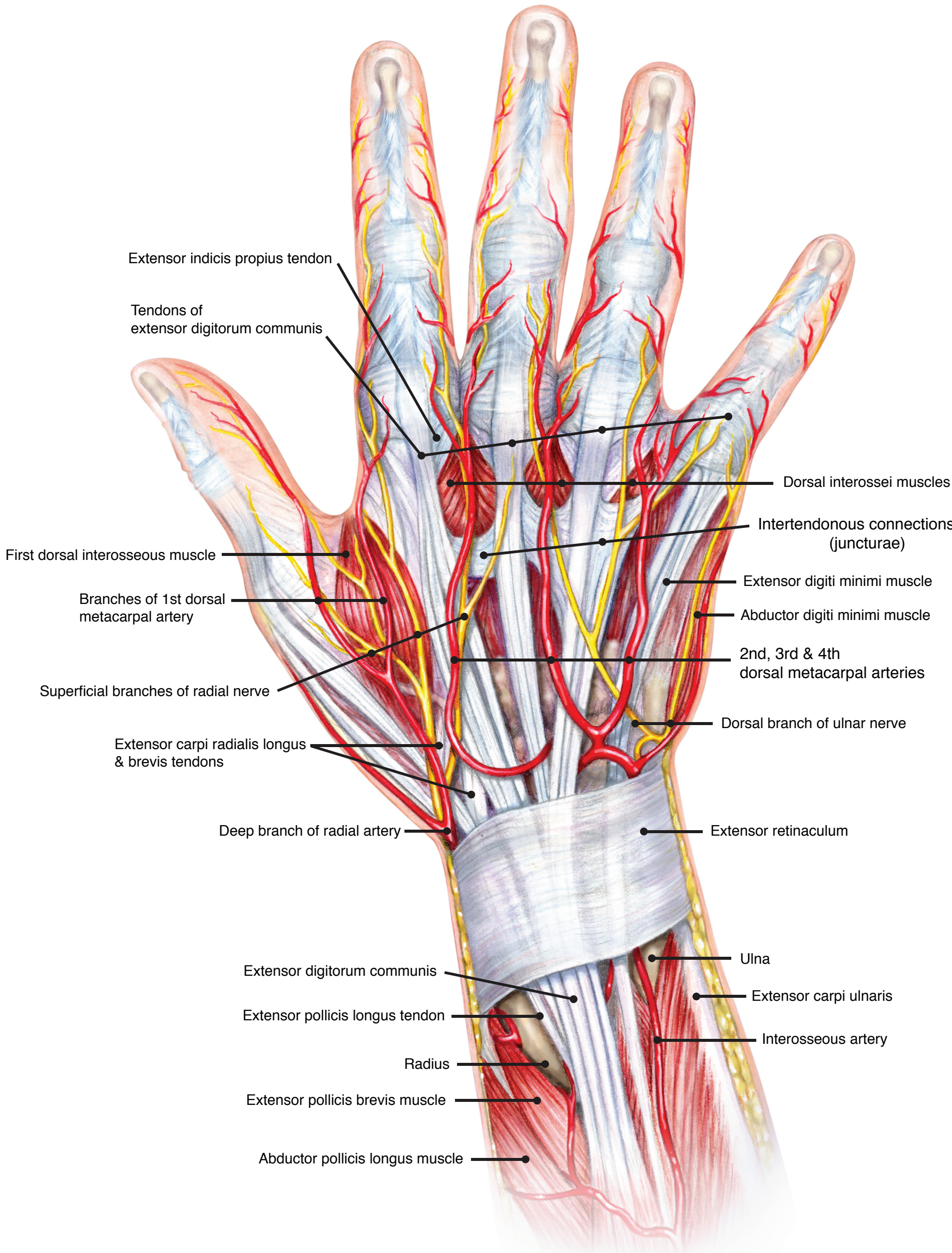
Skeletal Hand

1 Distal phalanges	6 3 rd metacarpal	11 Scaphoid	16 Pisiform
2 Middle phalanges	7 2 nd metacarpal	12 Radius	17 Hamate
3 Proximal phalanges	8 1 st metacarpal	13 Ulna	18 Capitate
4 5 th metacarpal	9 Trapezoid	14 Lunate	
5 4 th metacarpal	10 Trapezium	15 Triquetrum	

VariAx™ Dorsal and Volar Distal Radius Plating System



ANATOMY OF DORSAL HAND



stryker®